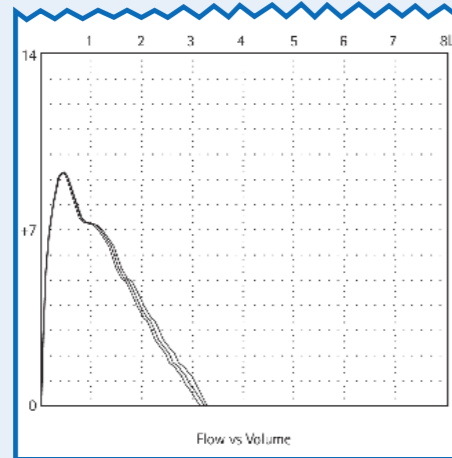
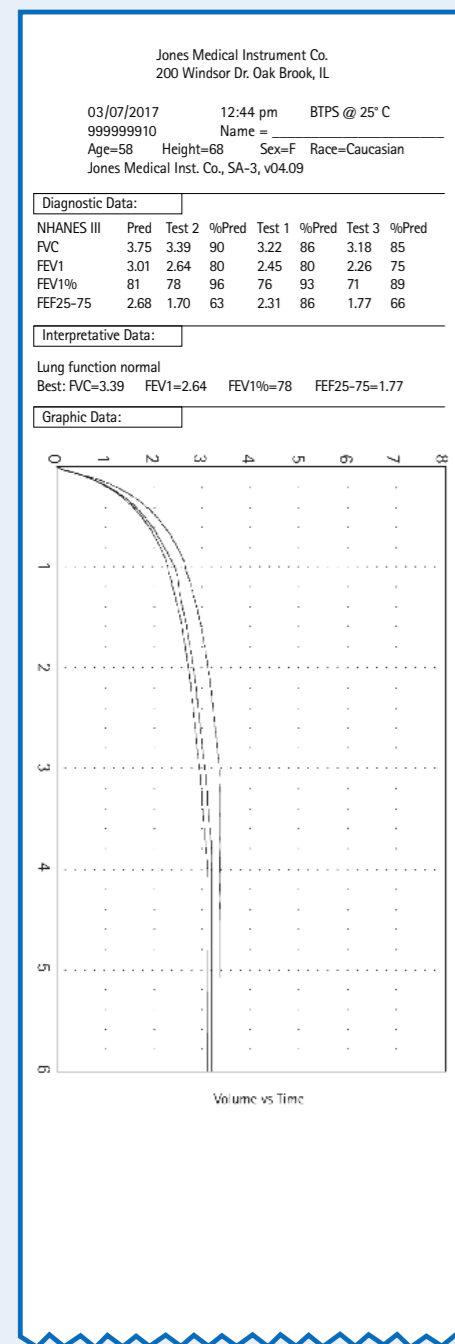


Normal: Overlaid Curves

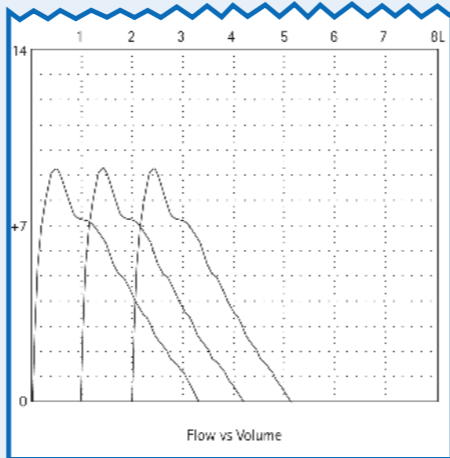
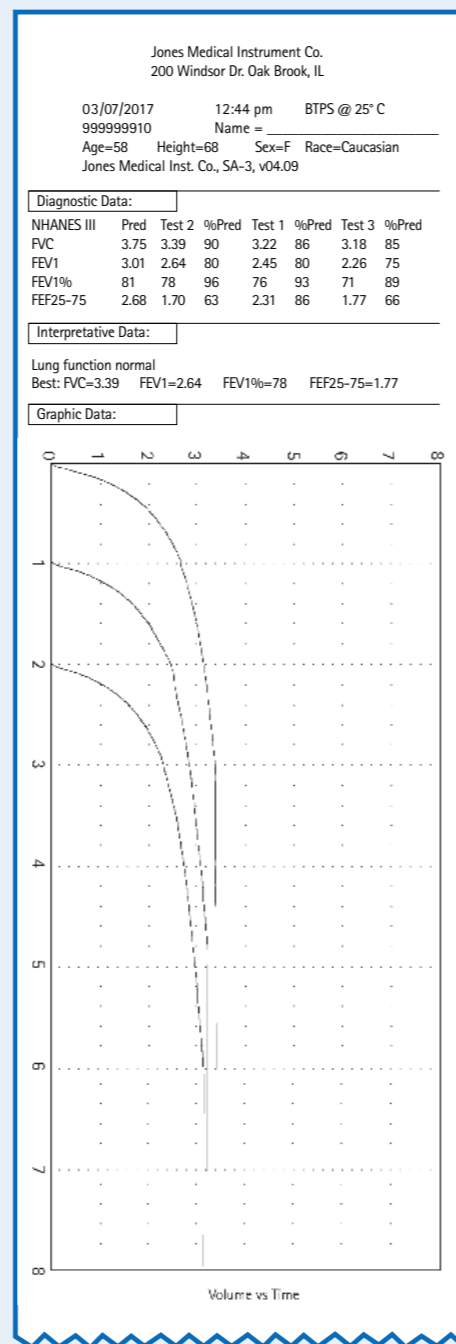


This printout shows three very similar curves overlaid on top of each other. Notice that there is very little variability between maneuvers.

In a normal volume vs time graph, the curve rises rapidly to the plateau and is sustained for at least 6 seconds. The "higher" the curve, the greater the volume of air exhaled. The volume vs time curves depicted here demonstrate an "ideal" result showing the patient gave his or her best effort. Note the sudden upsweep of the curve from the zero point, rapidly reaching a plateau.

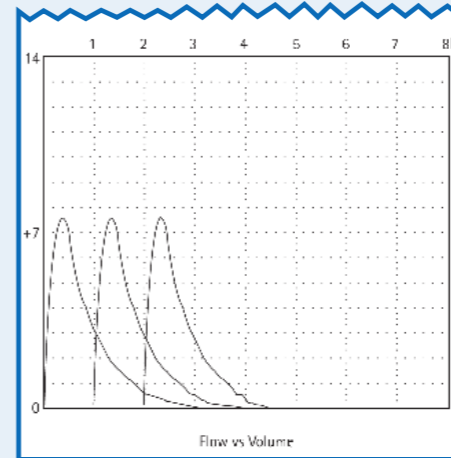
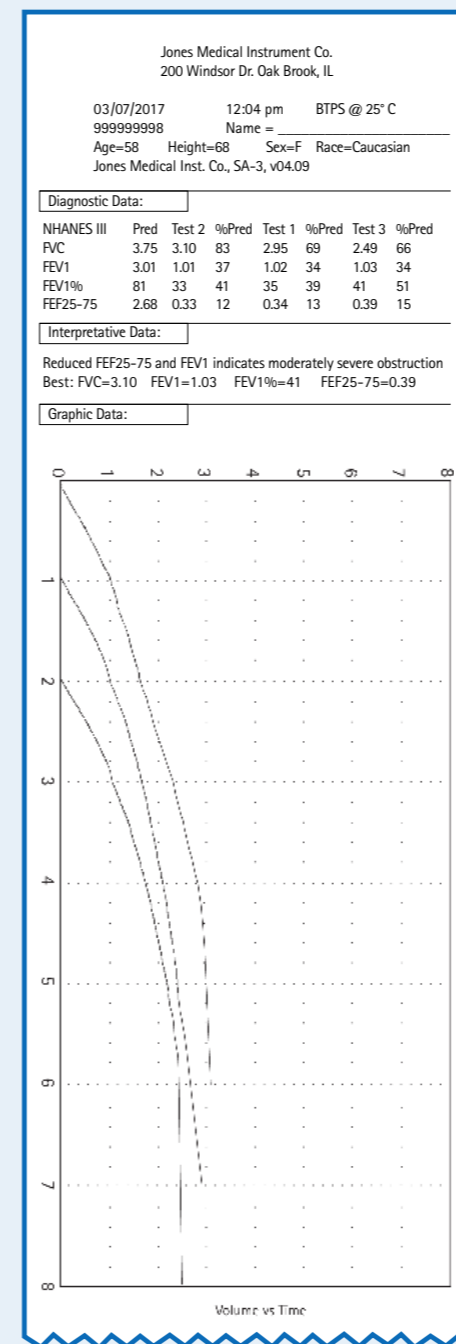
In a normal flow vs volume graph, the curve will look like the sail on a boat, rising rapidly from the baseline to a peak expiratory flow and then sloping downward back to baseline as the flow slows toward the end of exhalation. Notice that the flow vs volume graph is not a times tracing. The flow vs volume curves depicted here demonstrate an "ideal" result showing the patient gave his or her best effort. Note the sail shape of the curves.

Normal: Separate Curves



This is an example of a typical FVC test report from the Satellite/Base Station. The Satellite can also perform FVL and Post-Bronchodilator testing and display up to 20 different spirometric parameters. Virtually every aspect of the report can be customized to suit the specific needs of the user.

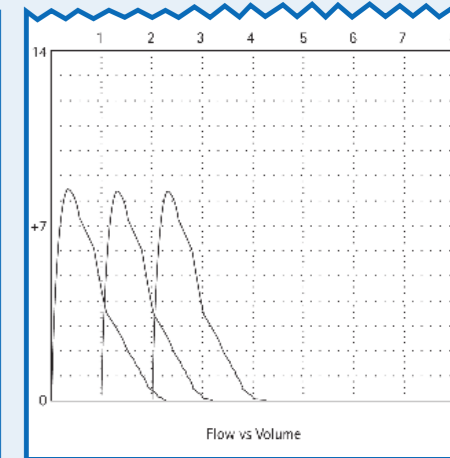
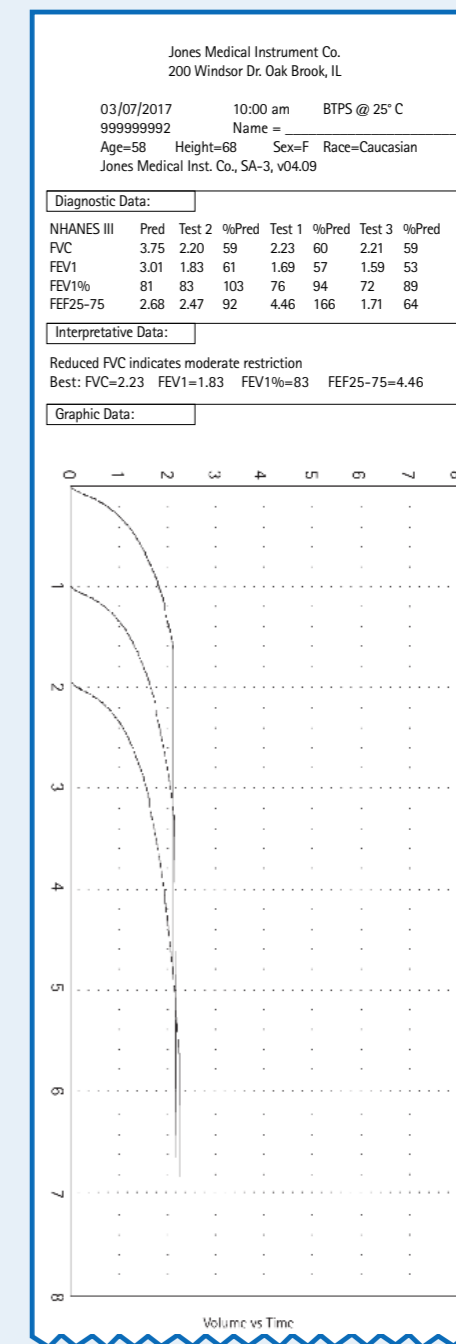
Obstructive: Separate Curves



The shapes of both the volume vs time and flow vs volume curves are clearly abnormal. In the volume vs time graph, the curves show no sudden upsweep from the zero point; instead, the curves rise gradually, never reaching clear, sustained plateaus. This is characteristic of classic obstructive disease.

In the flow vs volume graph, notice how the tracings take on a concave or "scooped out" shape after reaching its peak. This is indicative of classic obstructive disease. Eventually, as airways obstruction worsens, the peak drops and the curves fall off dramatically in the shape of a "rat's tail."

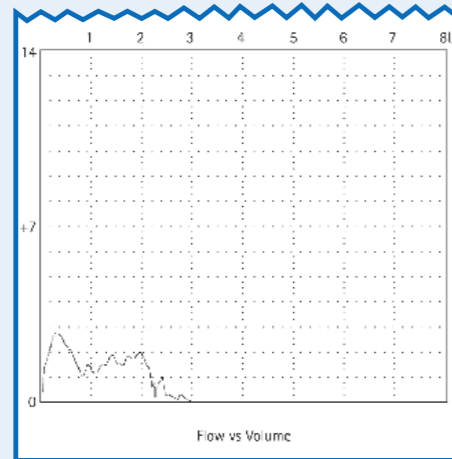
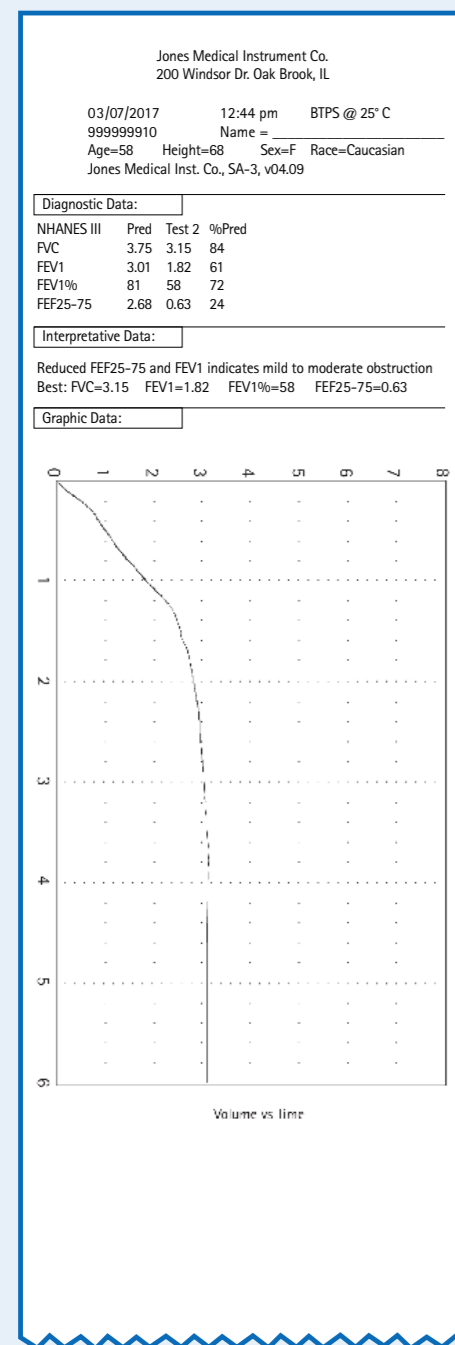
Restrictive: Separate Curves



Note that the shapes of these volume vs time and flow vs volume restrictive tracings start out looking normal. In the volume vs time tracings, there is a rapid upsweep from the zero point to the plateau; however, the height of the curve is lower than normal. This is characteristic of restrictive lung disease. Patients with restrictive disease are able to exhale at a normal or accelerated rate of airflow, but have trouble inhaling a deep breath to get started.

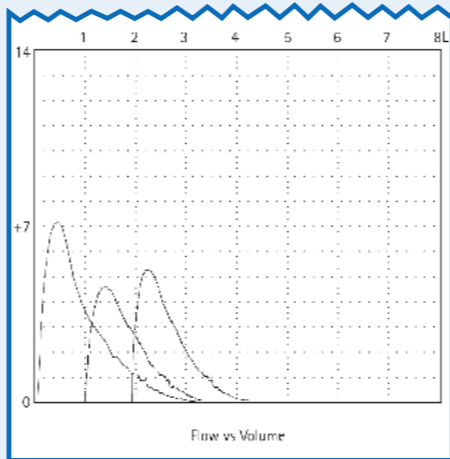
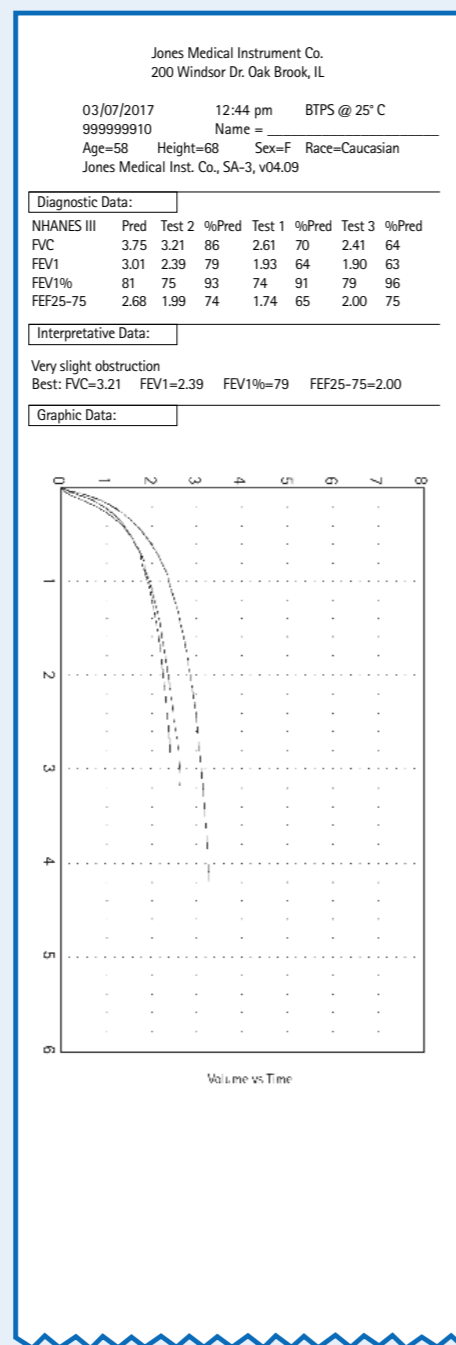
As with the volume vs time tracing, the flow vs volume tracing of patients with restrictive disease will typically look like a normal curve only in miniature form. That's because the flow rate is normal while the exhaled volume is reduced.

Obstruction of the Mouthpiece



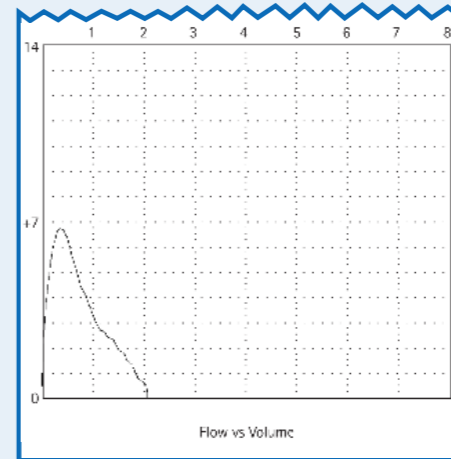
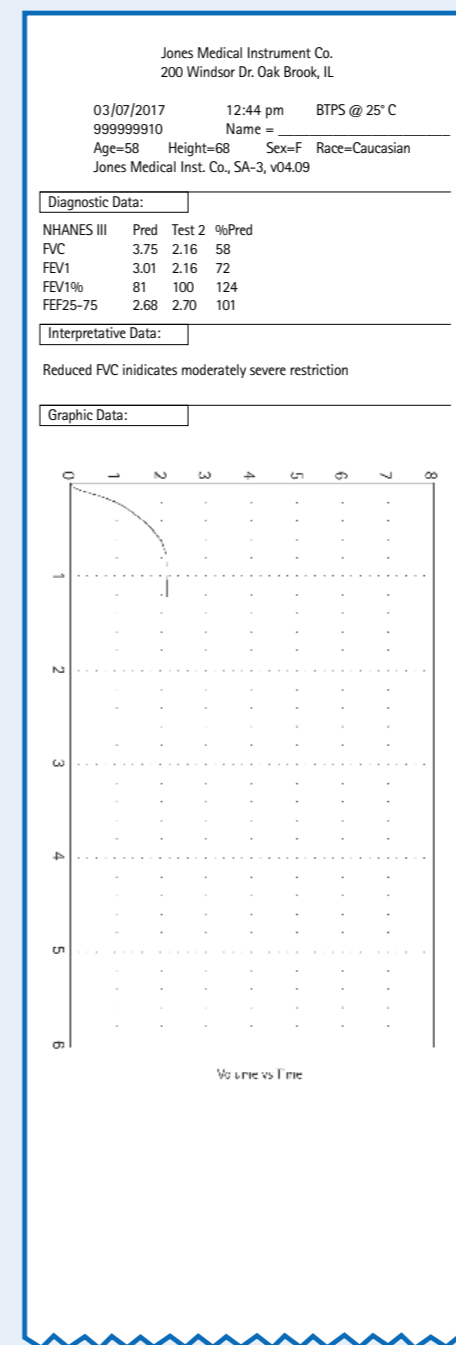
During a test, patients may inadvertently obstruct the mouthpiece with their tongue or ill-fitting dentures. The bumps on the tracings illustrate that air did not properly enter the mouthpiece due to obstruction. To obtain accurate results, patients should be counseled to move their tongue out of the way of the mouthpiece and/or to remove their dentures to prevent mouthpiece obstruction.

Nonconsistent Maneuvers



Note that the three tracings depicted in the volume vs time and the flow vs volume graphs do not match. This is evidence of a patient failing to give a consistent best effort with each maneuver, either because of a lack of understanding of the procedure or a lack of motivation to take in the deepest possible breath before exhaling. Patients usually stop too soon because they think they have exhaled completely. This is where coaching comes in, to keep the patient blowing out through the mouthpiece for at least 6 seconds. Lack of consistency between FVC maneuvers is equally evident whether you look at a volume vs time or flow vs volume tracing..

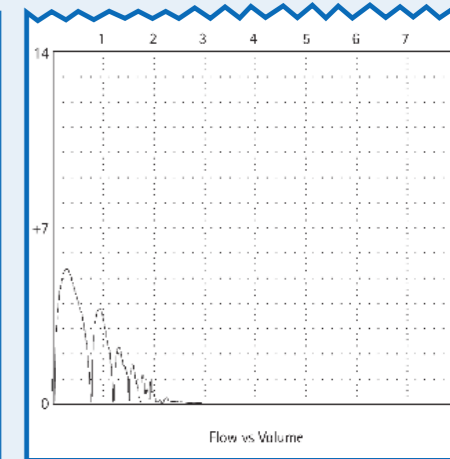
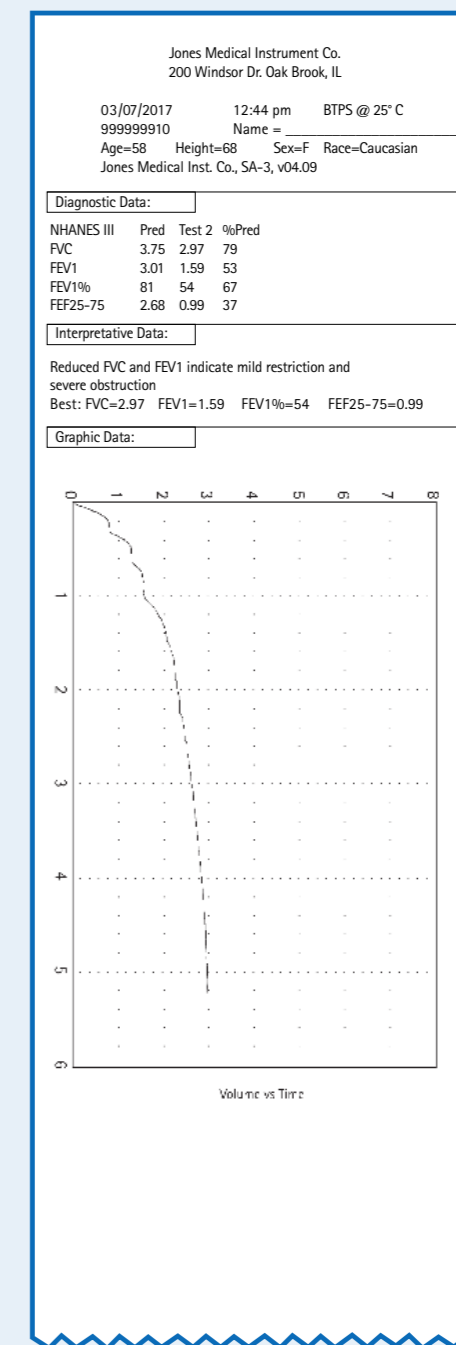
Ending Exhalation Too Soon



In this tracing, the patient stopped exhaling too soon — barely 1.5 seconds. This is common on the first exhalation for a patient who has never performed an FVC maneuver before. Patients usually stop too soon because they think they have exhaled completely. This is where coaching comes in to keep the patient blowing out through the mouthpiece for at least 6 seconds.

Ending exhalation too soon is clearly evident in the volume vs time curve where the curve stops abruptly. The flow vs volume curve depicts technique problems differently from the volume vs time curve. It is much more difficult, for example, to identify exhalation that ends too soon in a flow vs volume curve than in a volume vs time curve.

Coughing During the Test



The bumps in this curve correspond to slight coughs with the mouthpiece still in place. Usually, during testing, the technician hears the patient cough and rejects that effort, or the patient removes the mouthpiece to be able to cough. A tracing made while the patient is coughing is unacceptable. It is important to recognize this tracing in case the test is accepted and printed, and an interpretation is being done by someone who was not present during testing.

A flow vs volume curve dramatically depicts coughing during the test. Each bump in the tracing represents a cough. Coughing during the test is much harder to recognize on a volume vs time tracing.